

# Difficult Antegrade Reentry

Ashish Pershad MD FACC FSCAI

Cavanagh Heart Center @ Banner Good  
Samaritan Medical Center

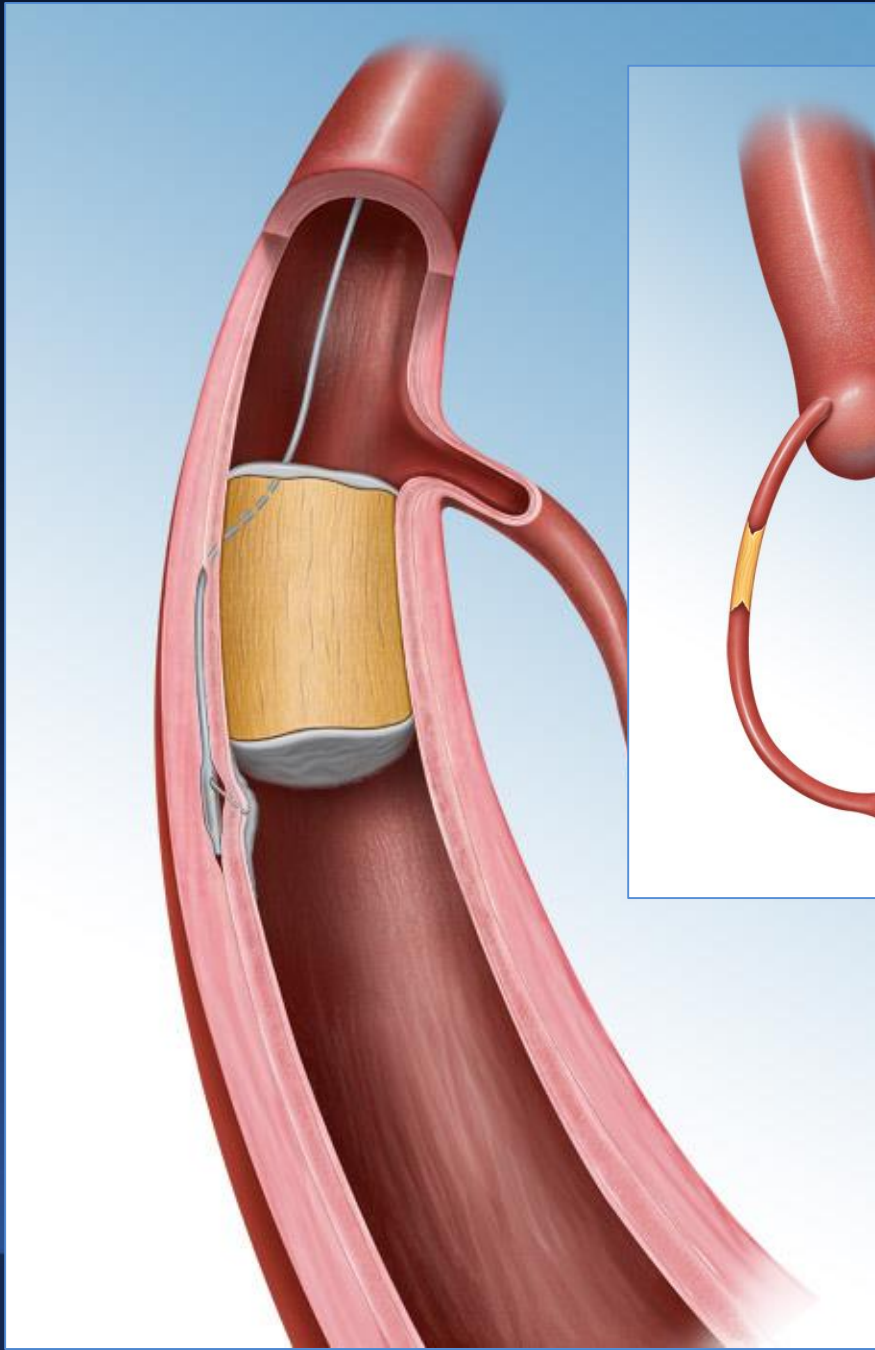
Phoenix AZ

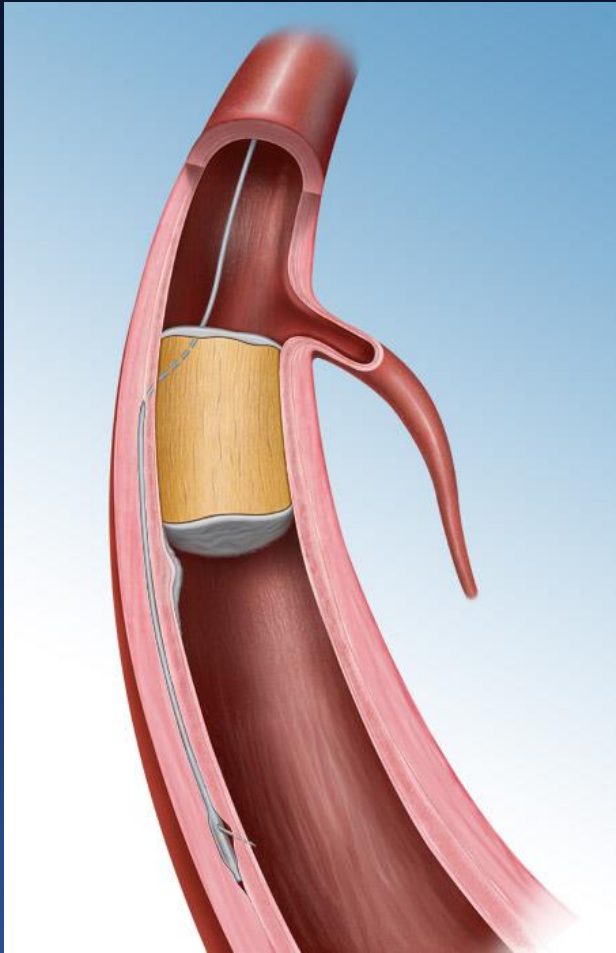
All faculty disclosures are available on  
the CRF Events App and online at  
[www.crf.org/tct](http://www.crf.org/tct)

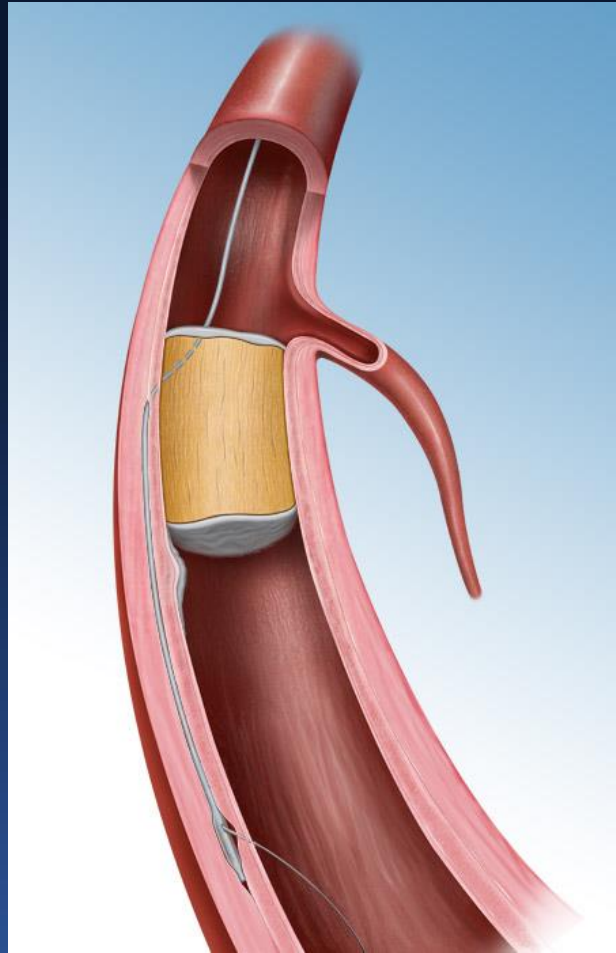
# Difficult Antegrade Re-Entry

<b><u>Problem</u></b>	<b>Failure to Reenter</b>	<b>Small vessel and diffuse disease</b>	<b>Subintimal Hematoma</b>
<b><u>Solutions</u></b>	<b>Bob-Sled</b>	<b>Stick and swap</b>	<b>STRAW-Cutting balloon</b>

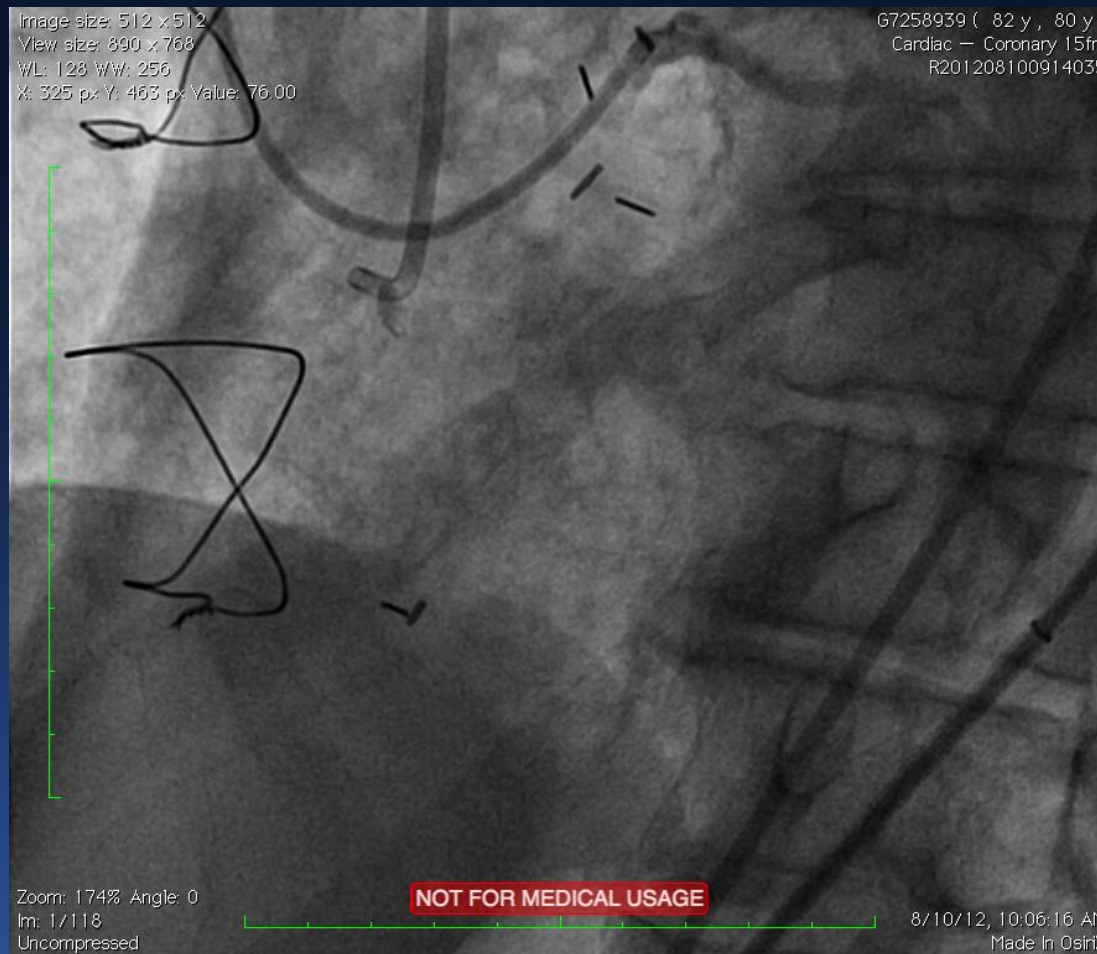
Solutions are not exclusive and frequently needed together to deal with difficult ADR cases



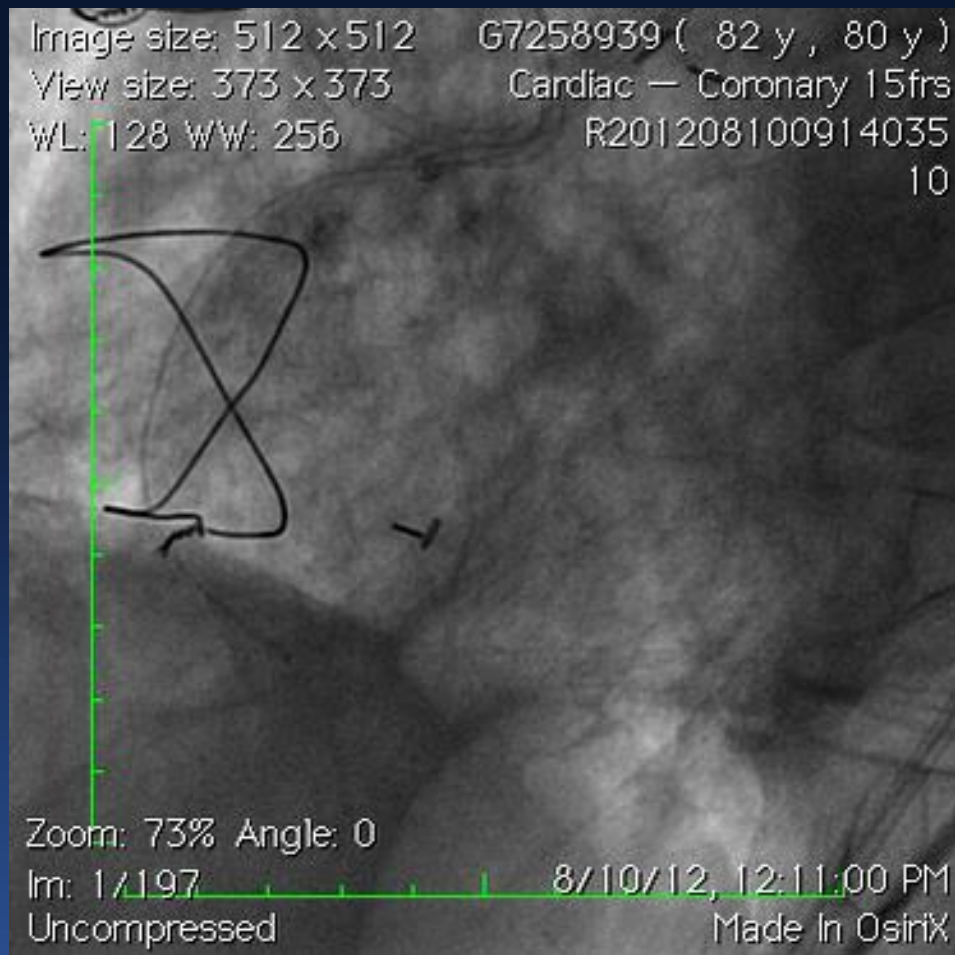




# Case 1- Inability to Re-Enter at Desired Location

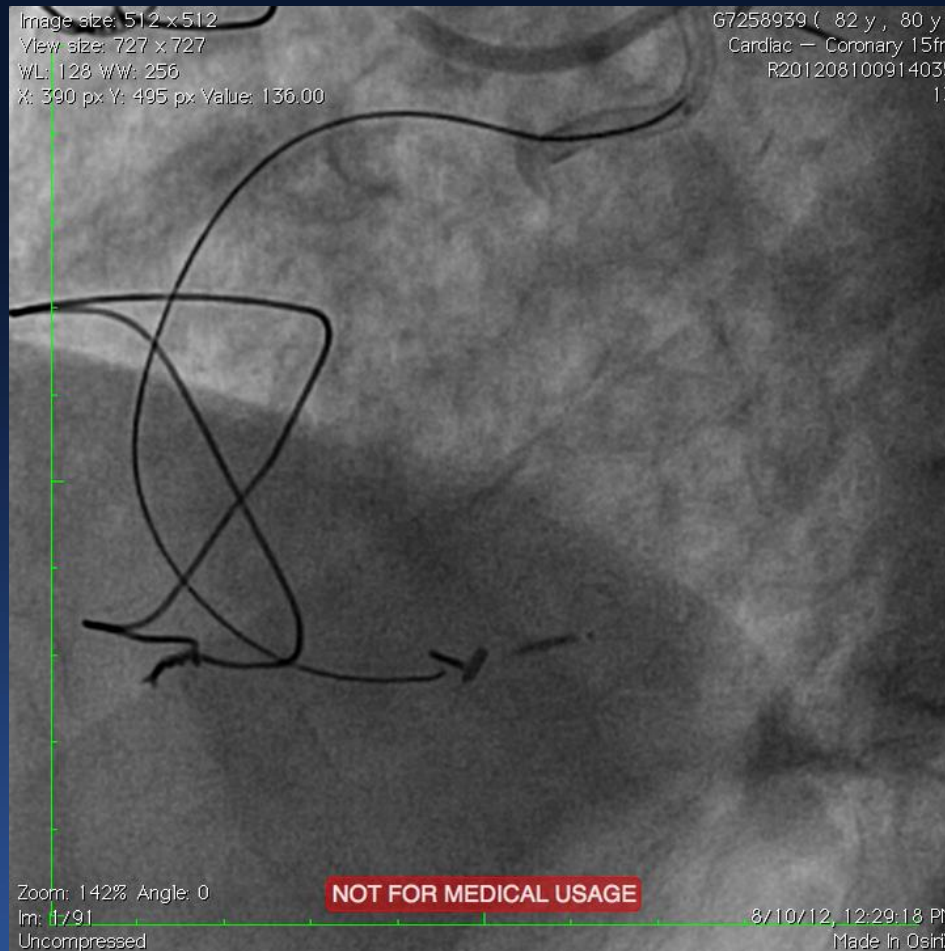


# Unable to perform ADR in this segment

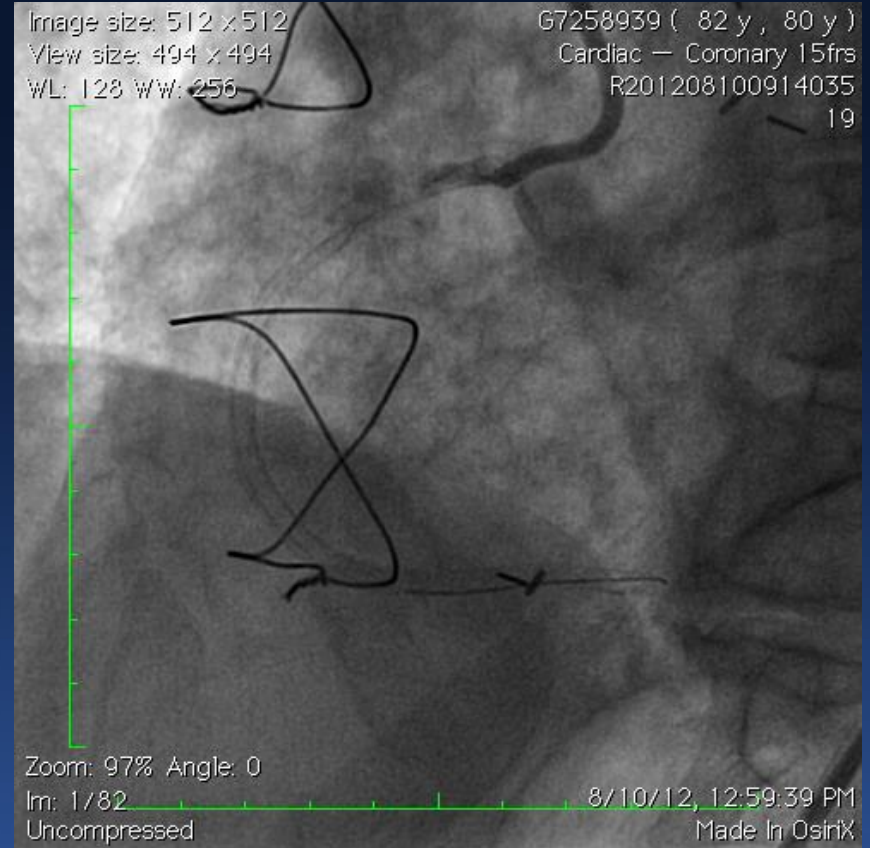
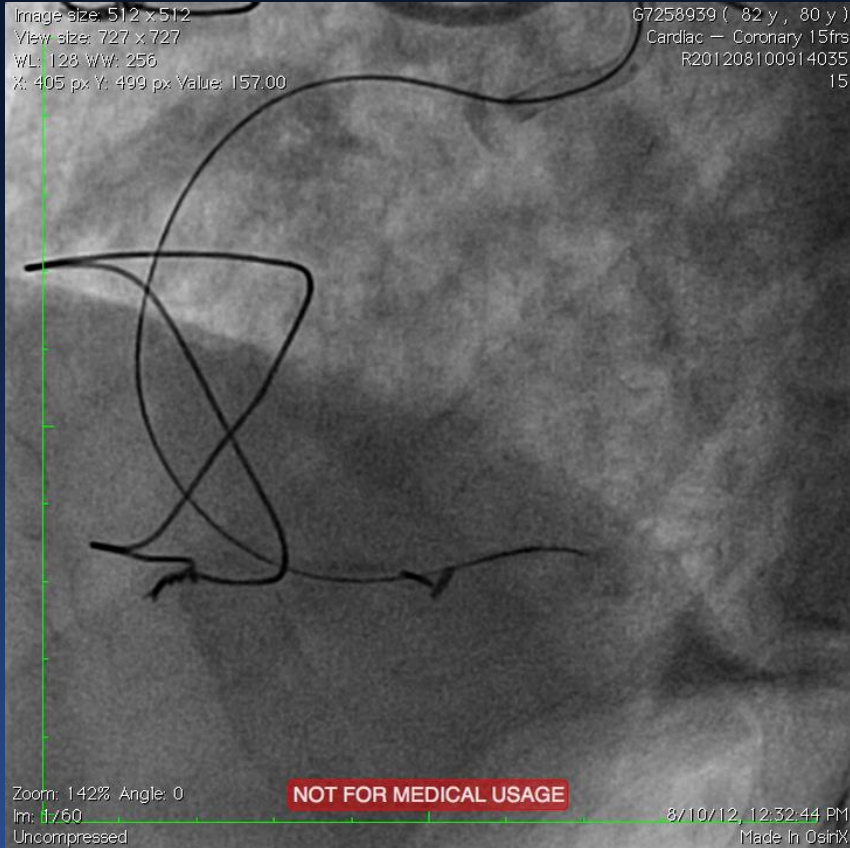




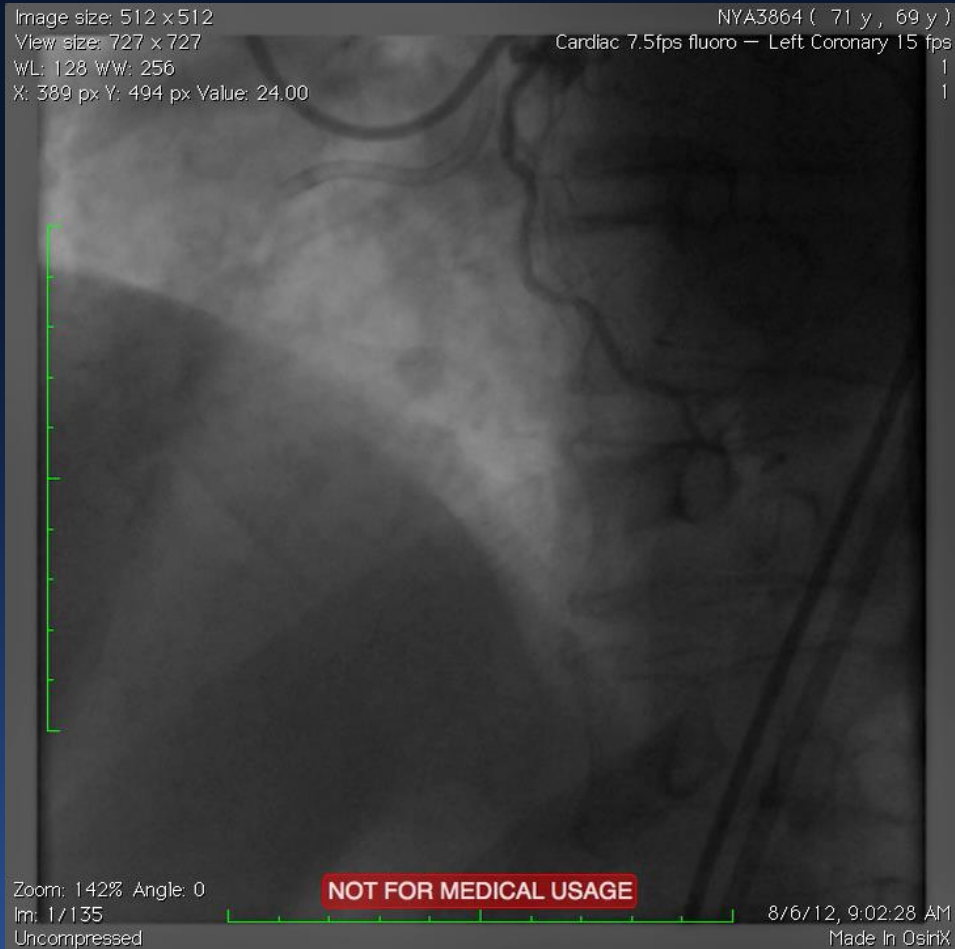
# Solution-“BOB SLED” to further down in vessel



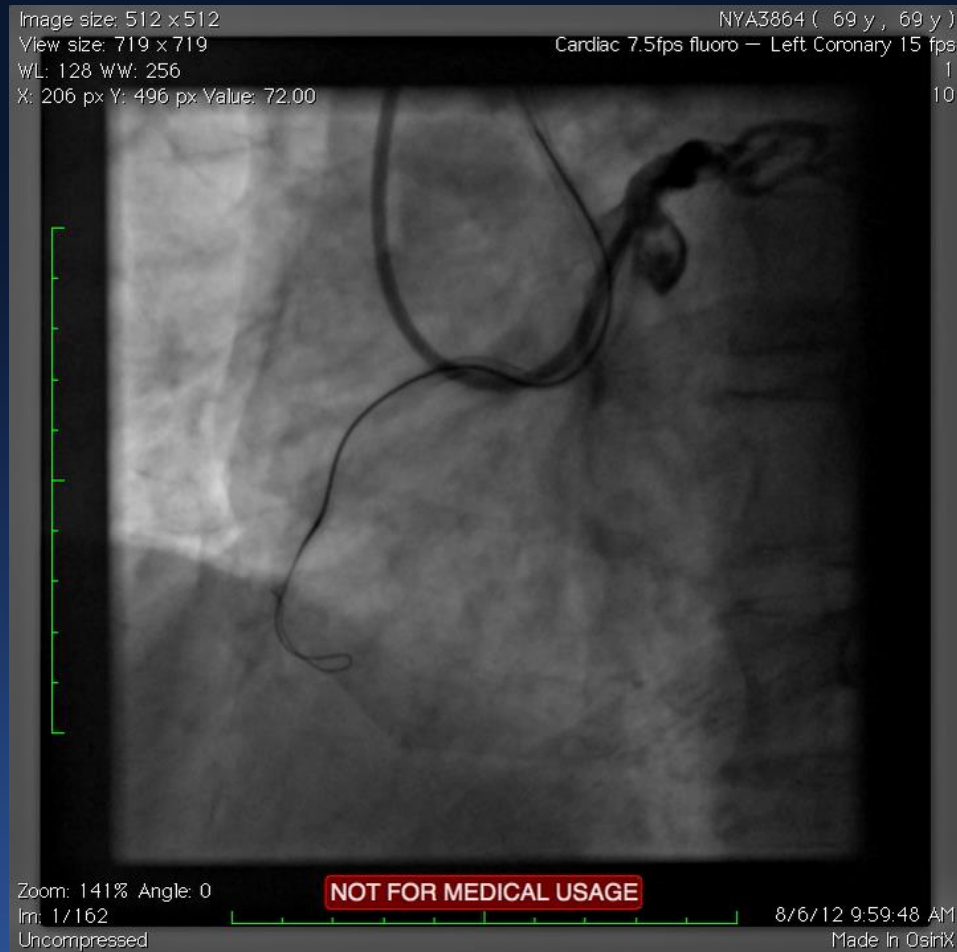
# Stick And Completion Angiogram

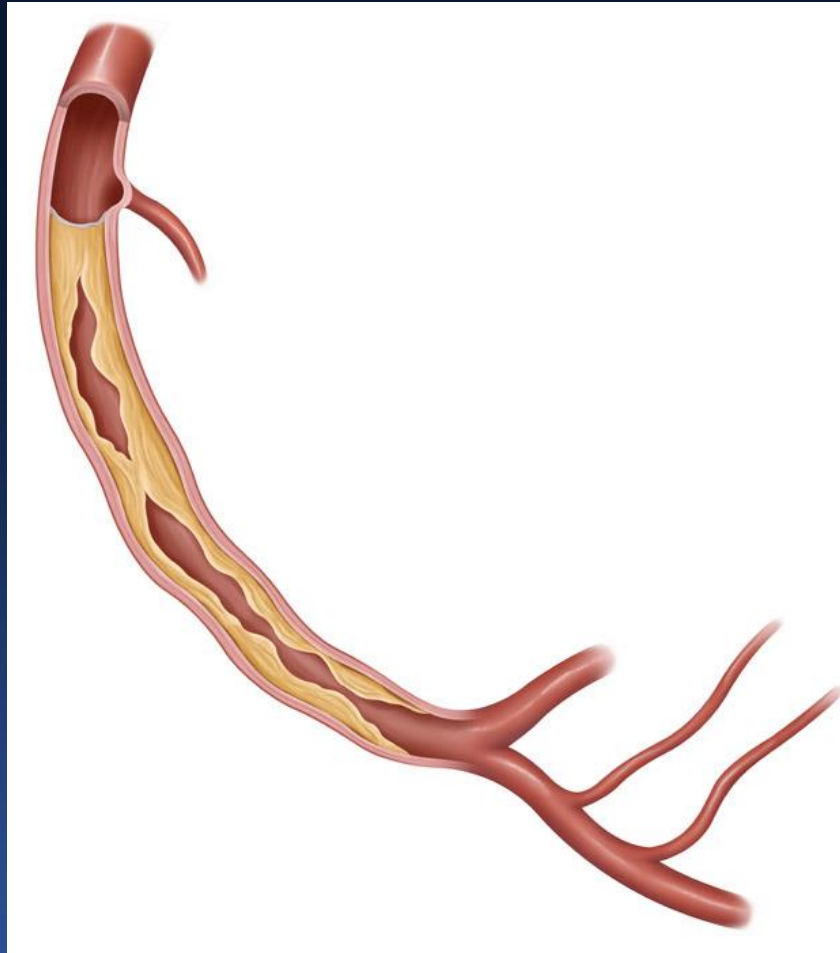


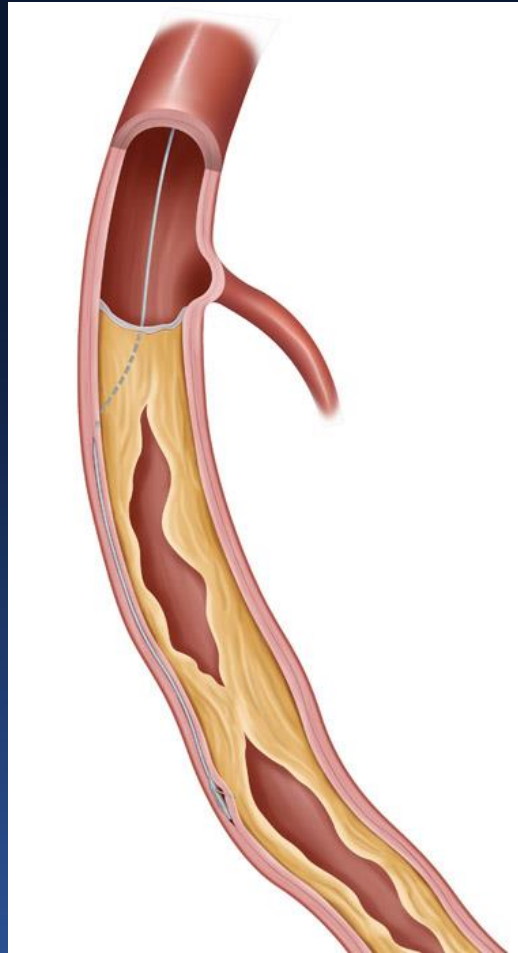
# Calcified CTO

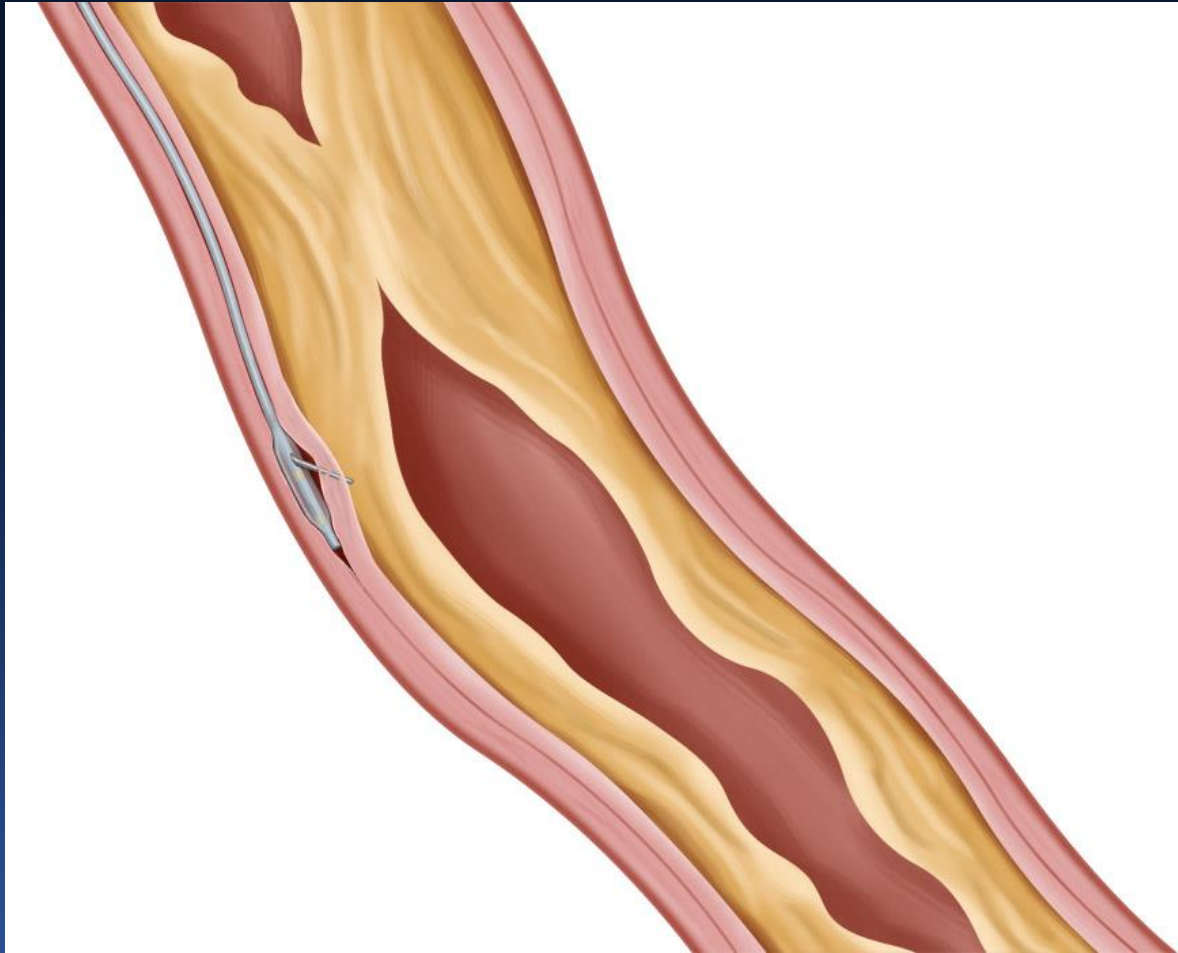


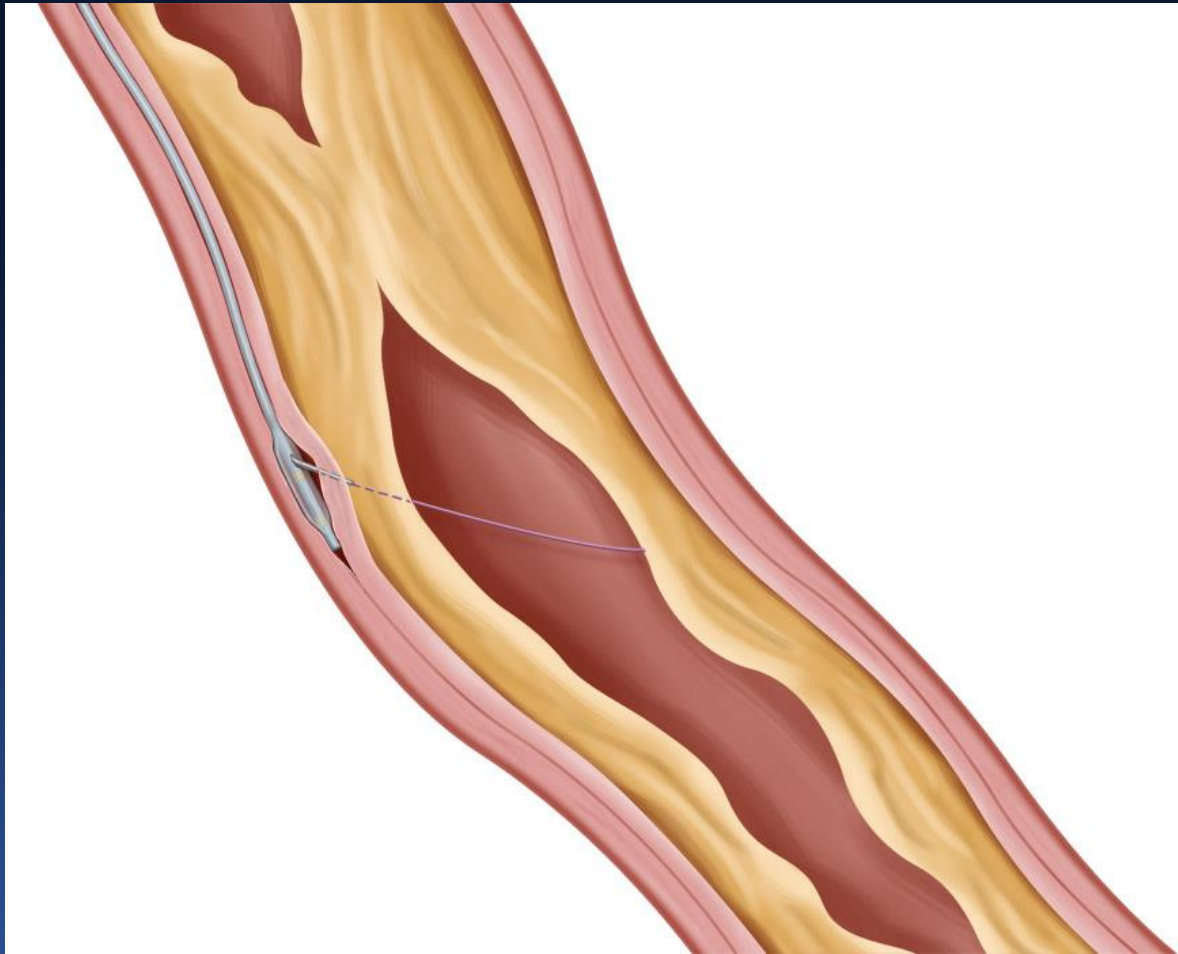
# ADR with “knuckled wire” down to landing zone



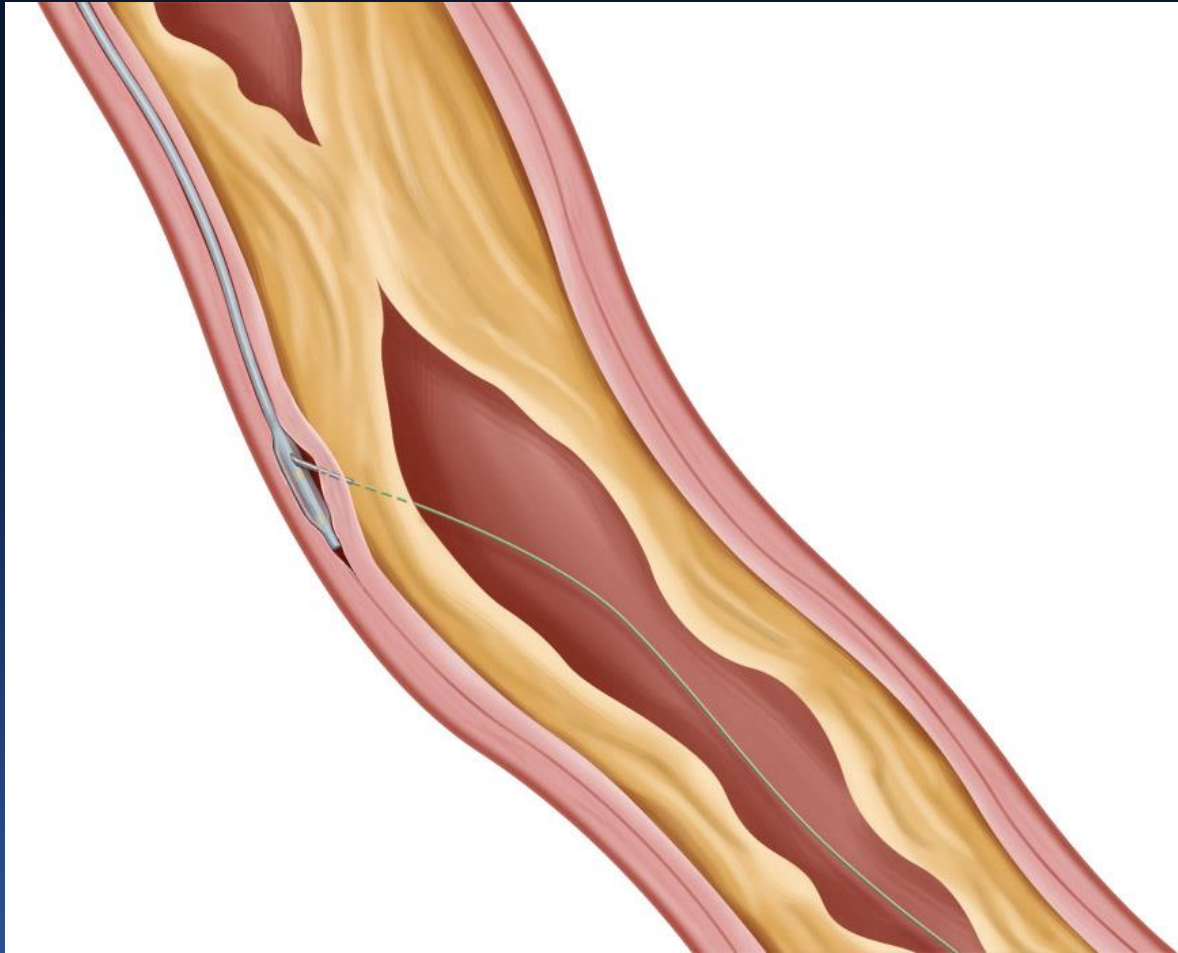




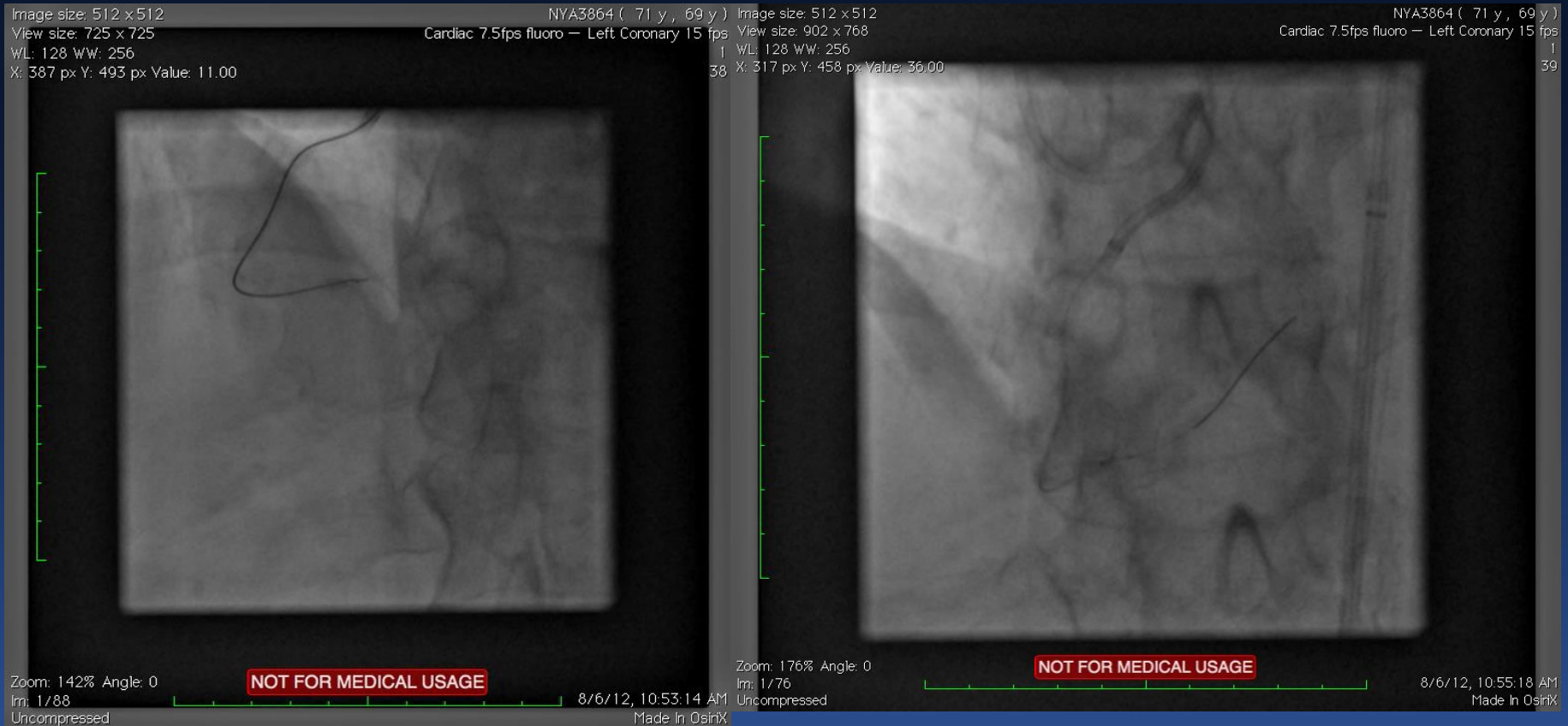




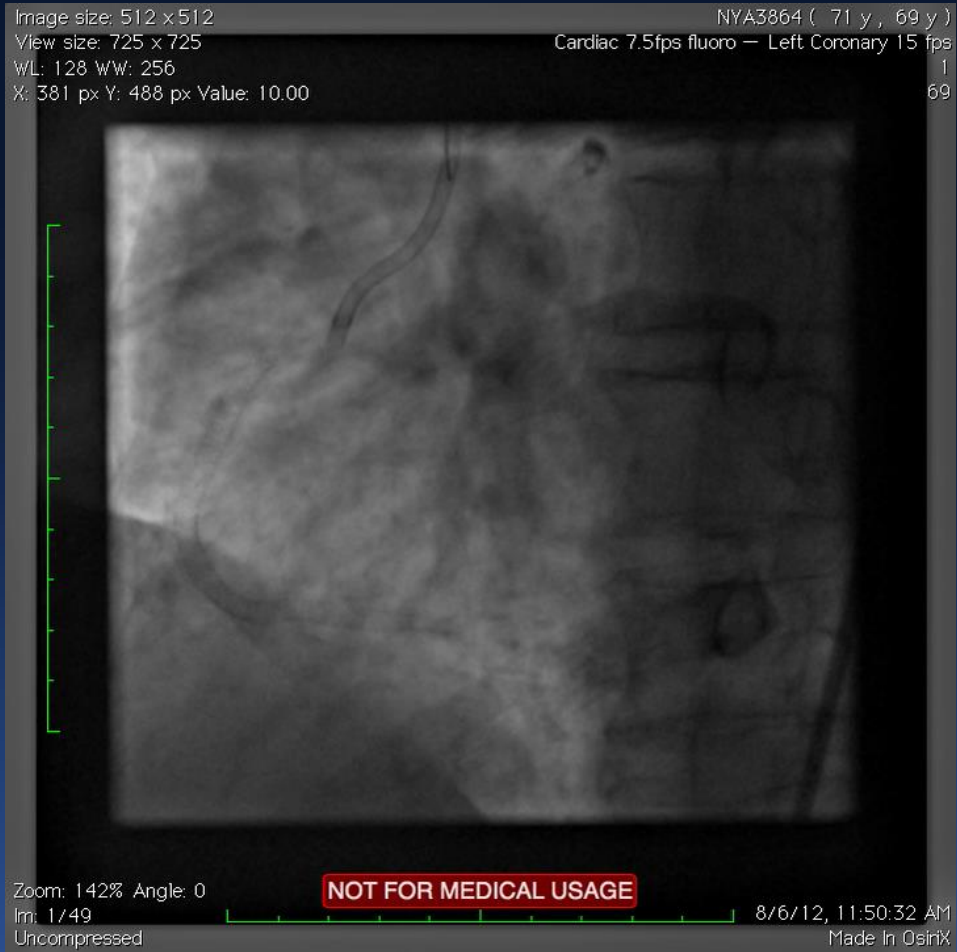




# “Stick and Swap”-Solution for small vessels and Extensive plaque burden

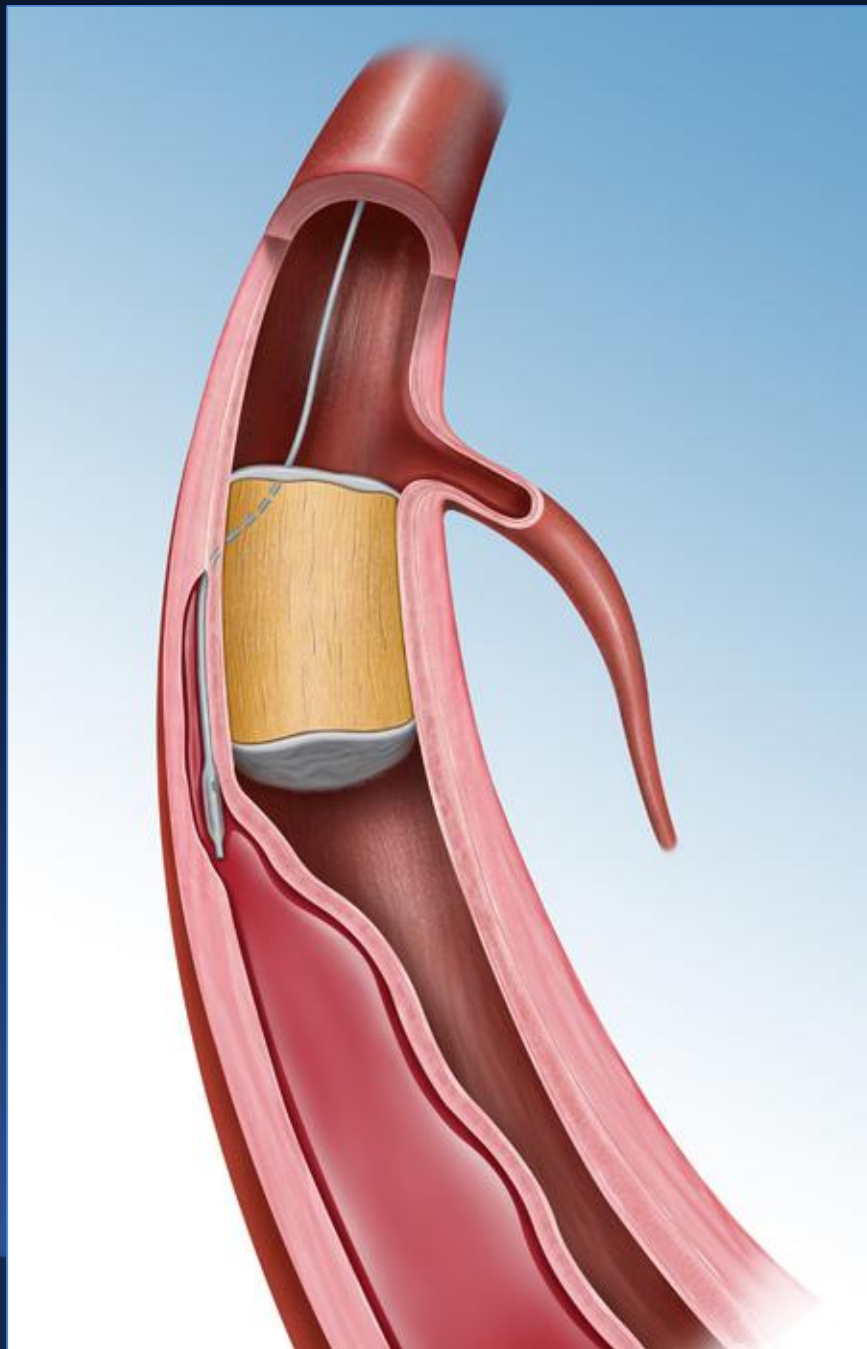


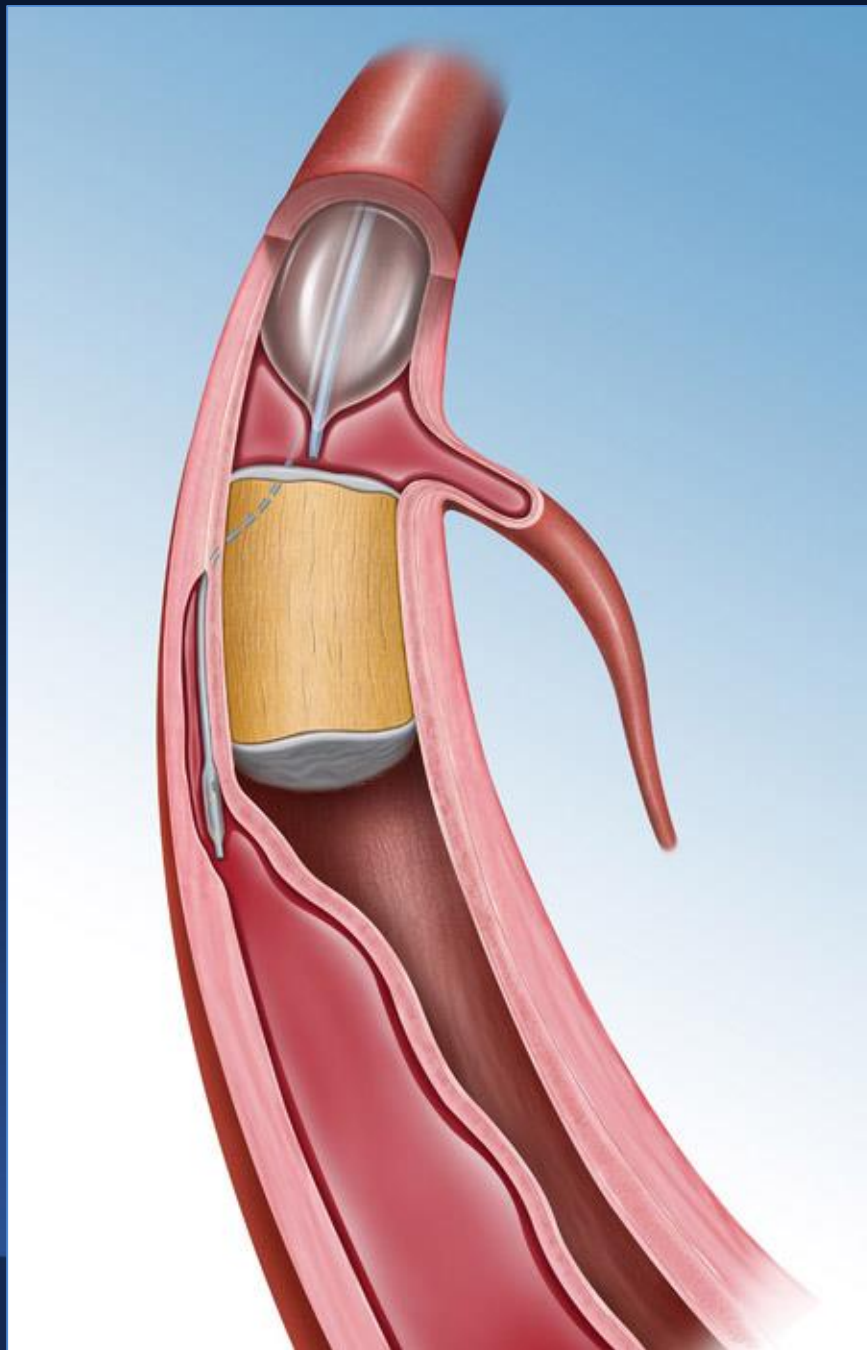
# Final angiogram

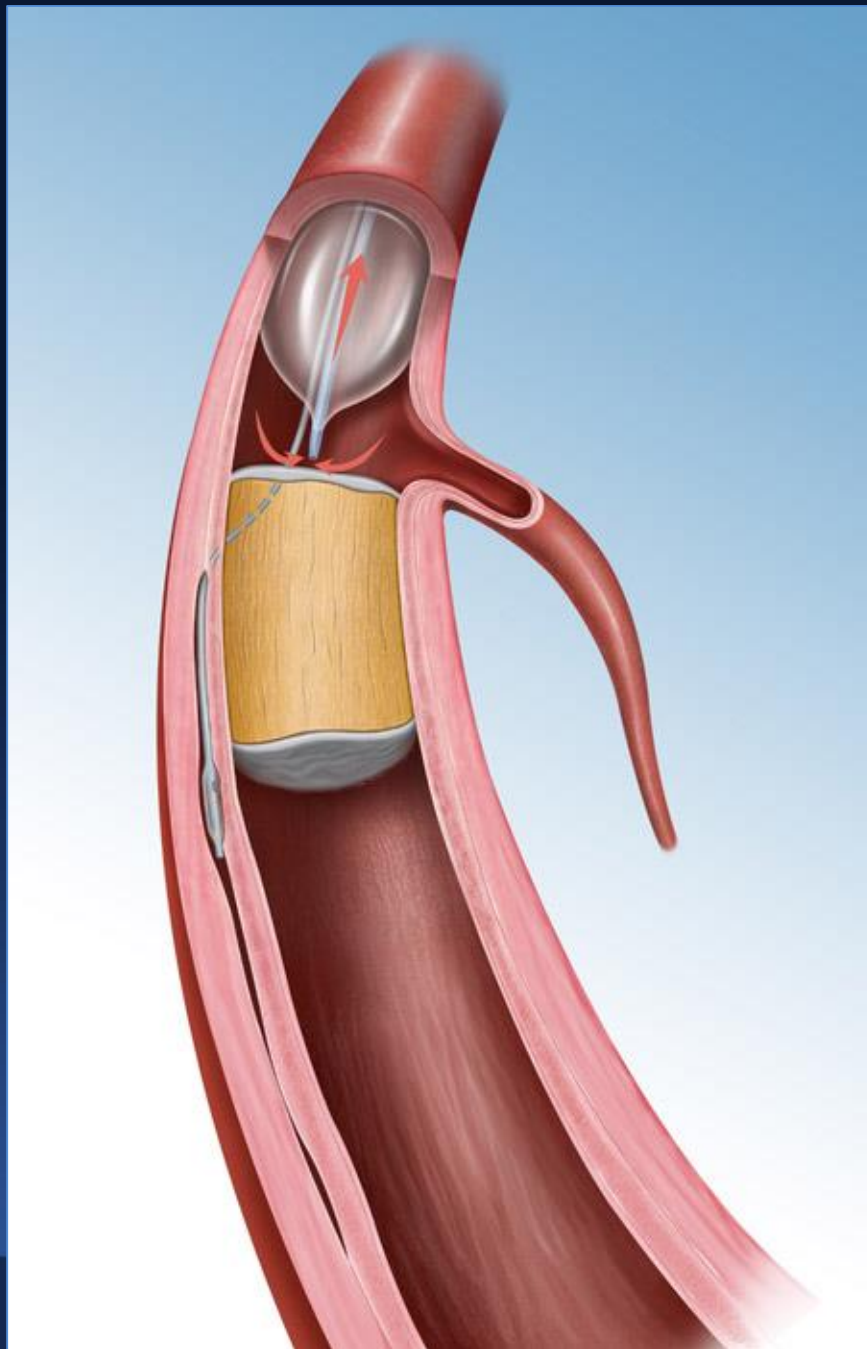


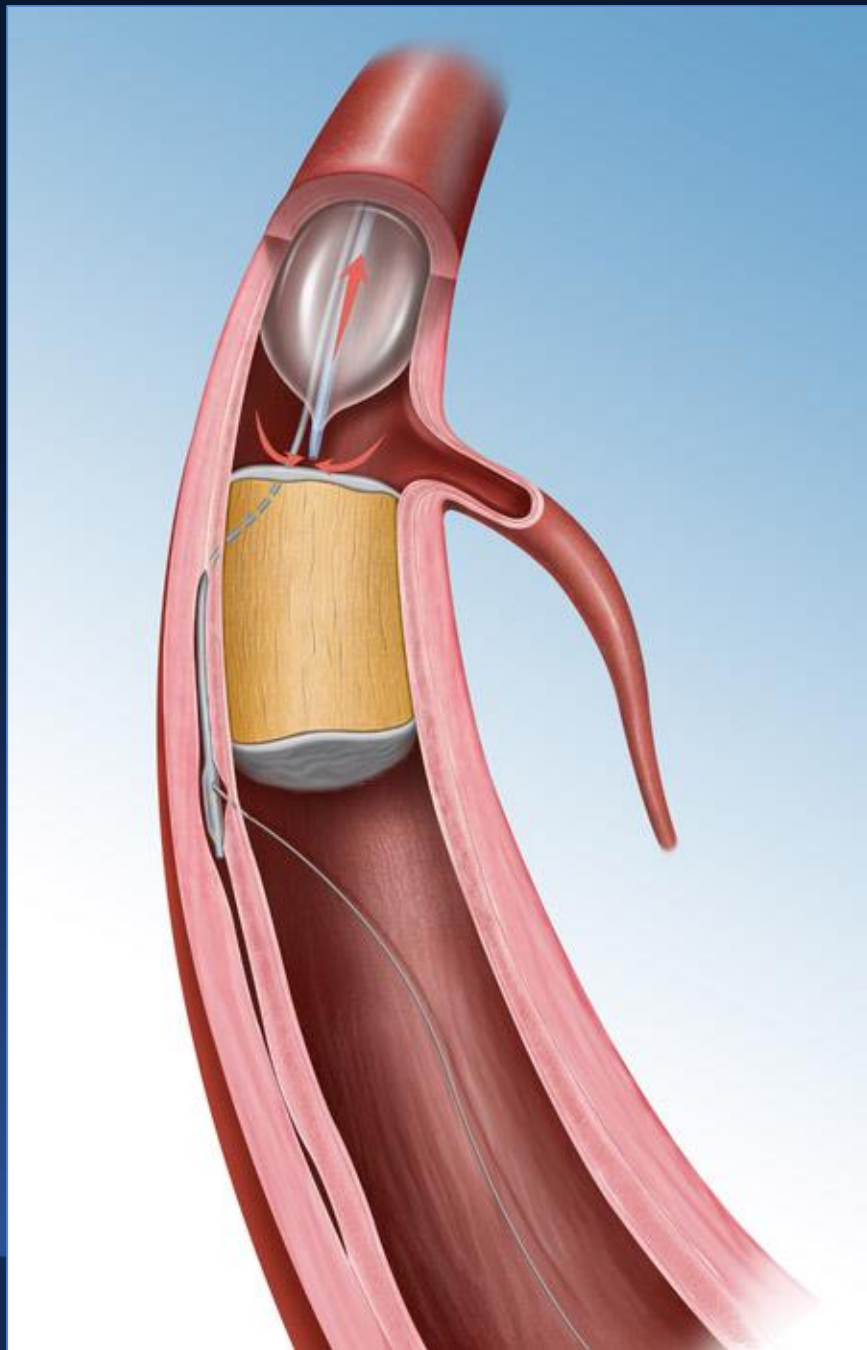
# Sub-Intimal Hematoma

- Impedes distal visualization of the vessel
- Makes ADR challenging
- Can be overcome with the following solutions:
  1. STRAW
  2. Modified STRAW
  3. Guideliner assisted STRAW
  4. STRAW via the wire lumen of the StingRay balloon



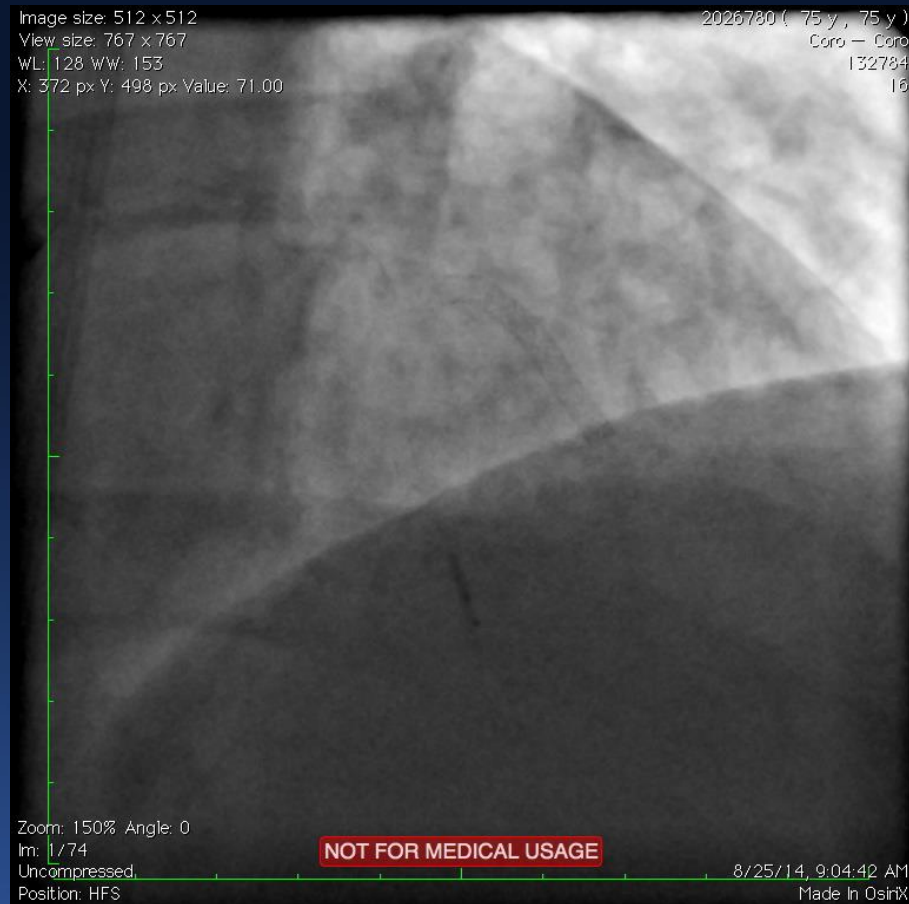




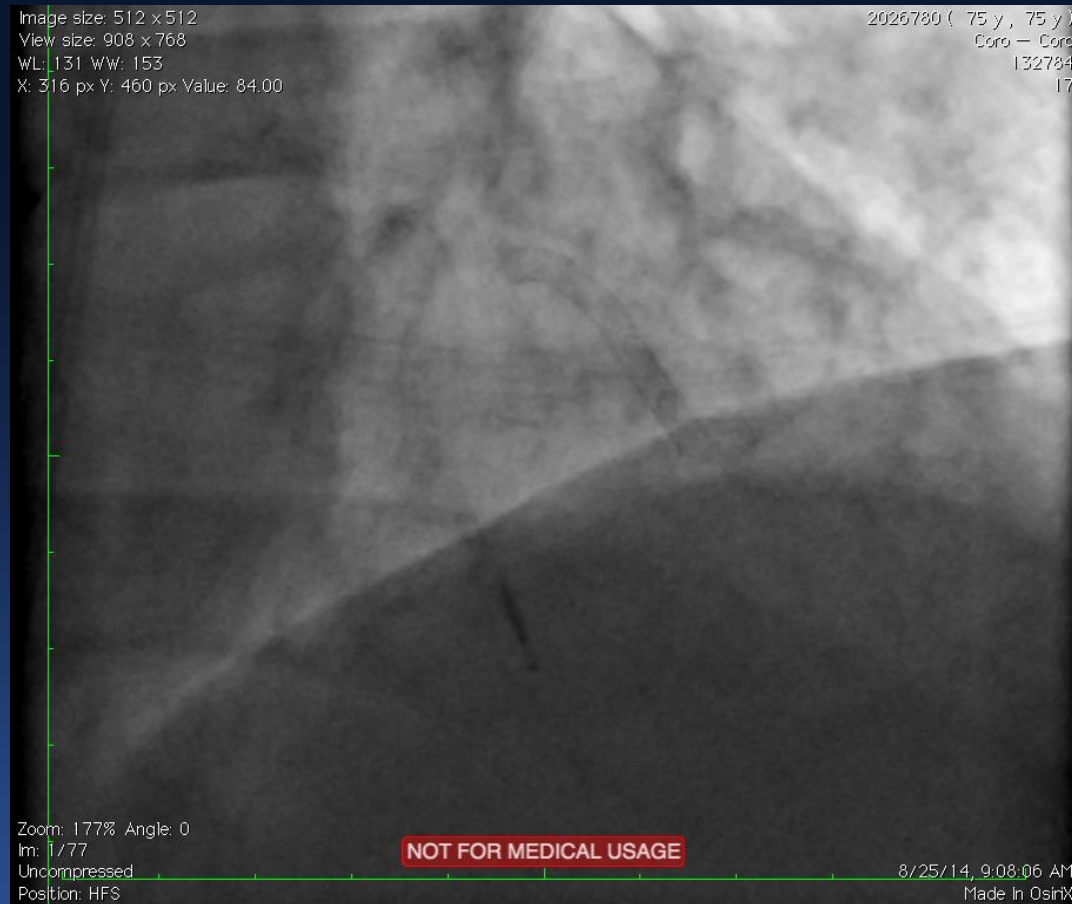



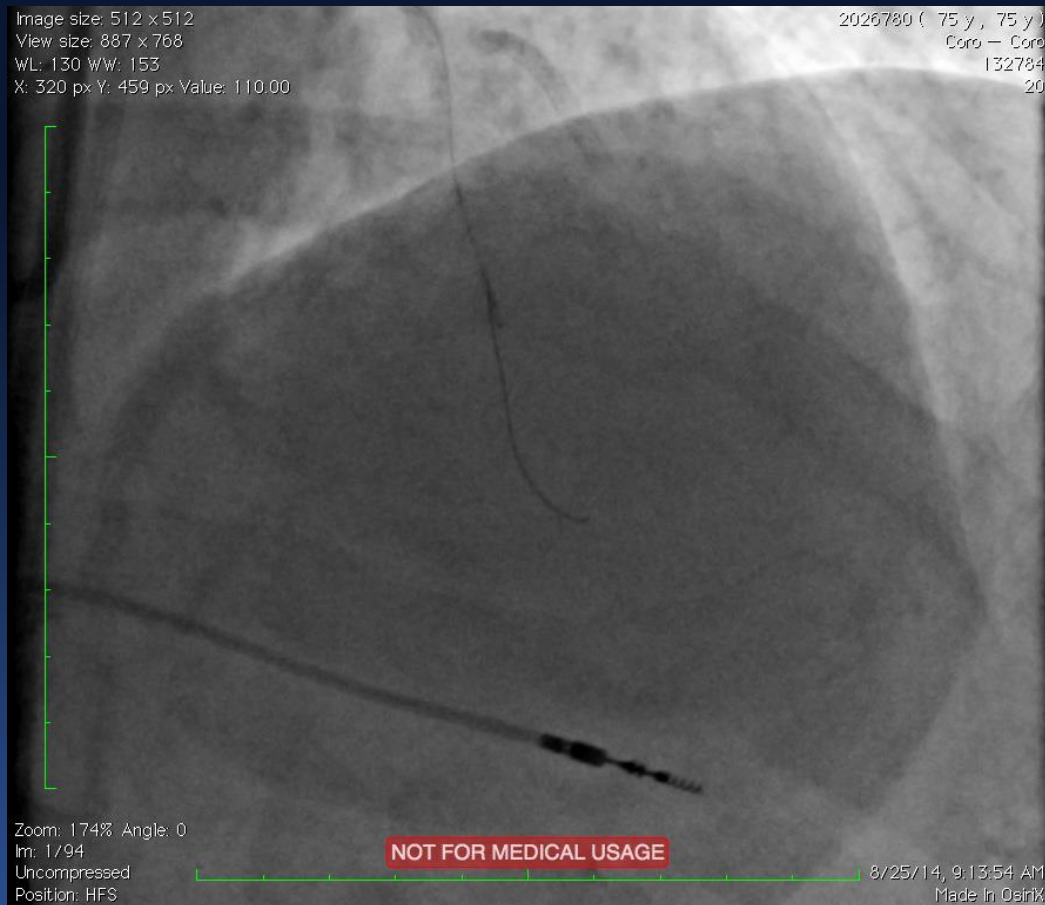
# Subintimal Hematoma-Prestraw (poor distal visualization)



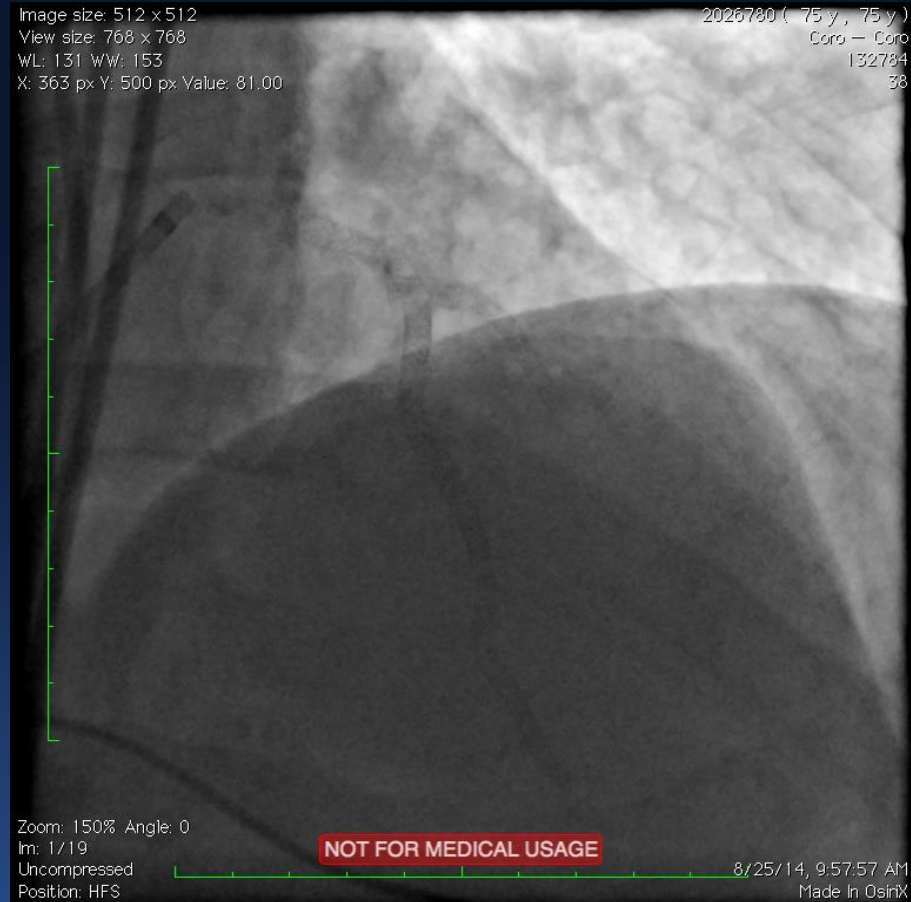
# Post STRAW-Improved visualization



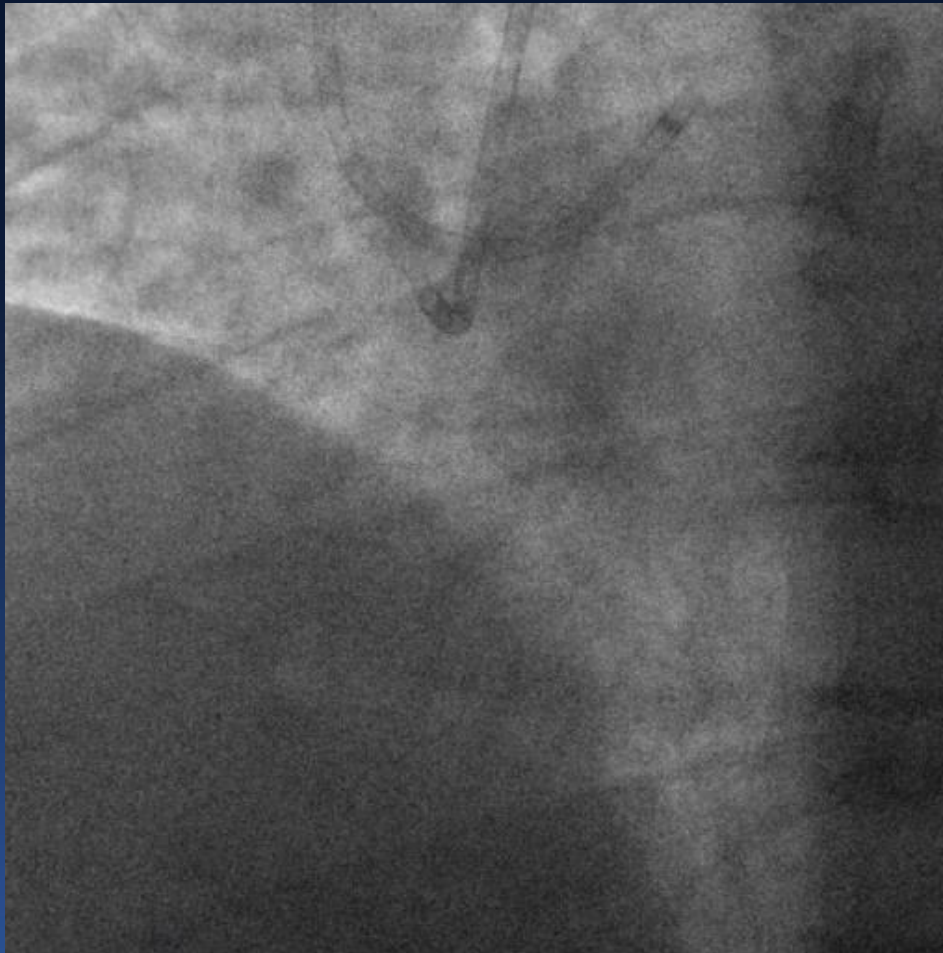
# Post STRAW- Re-entry with Stick and Swap



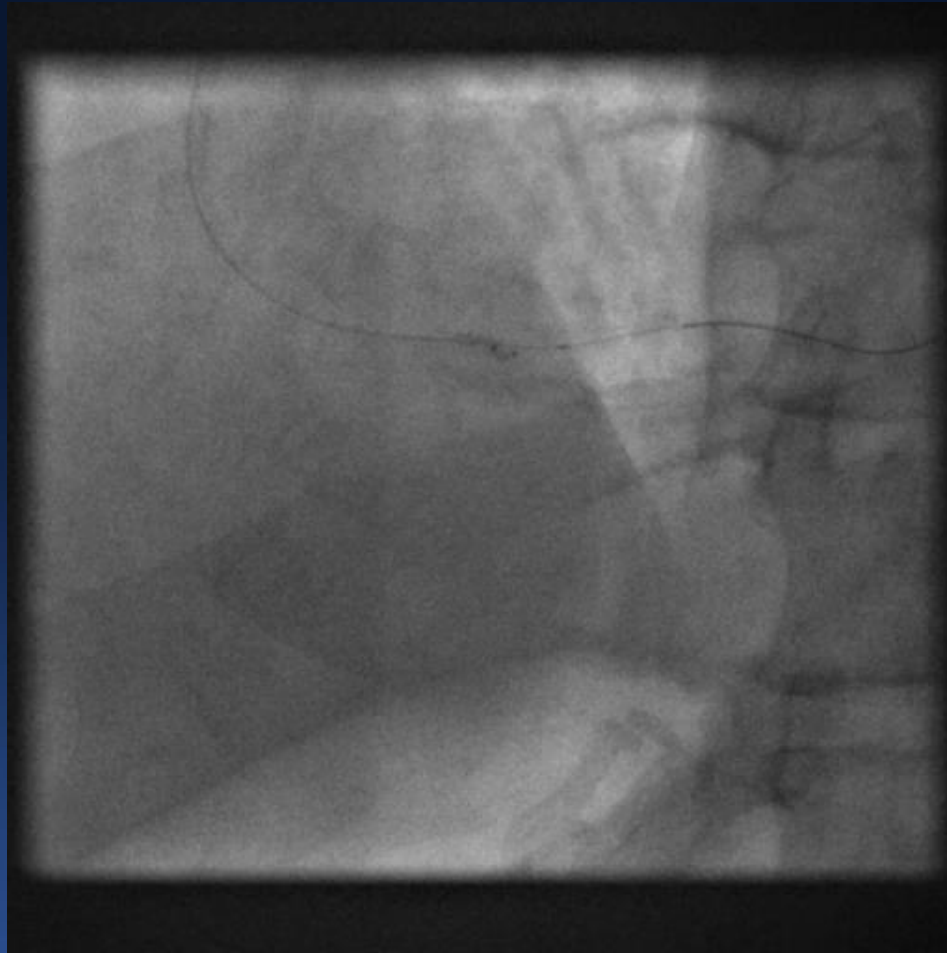
# Final angiogram



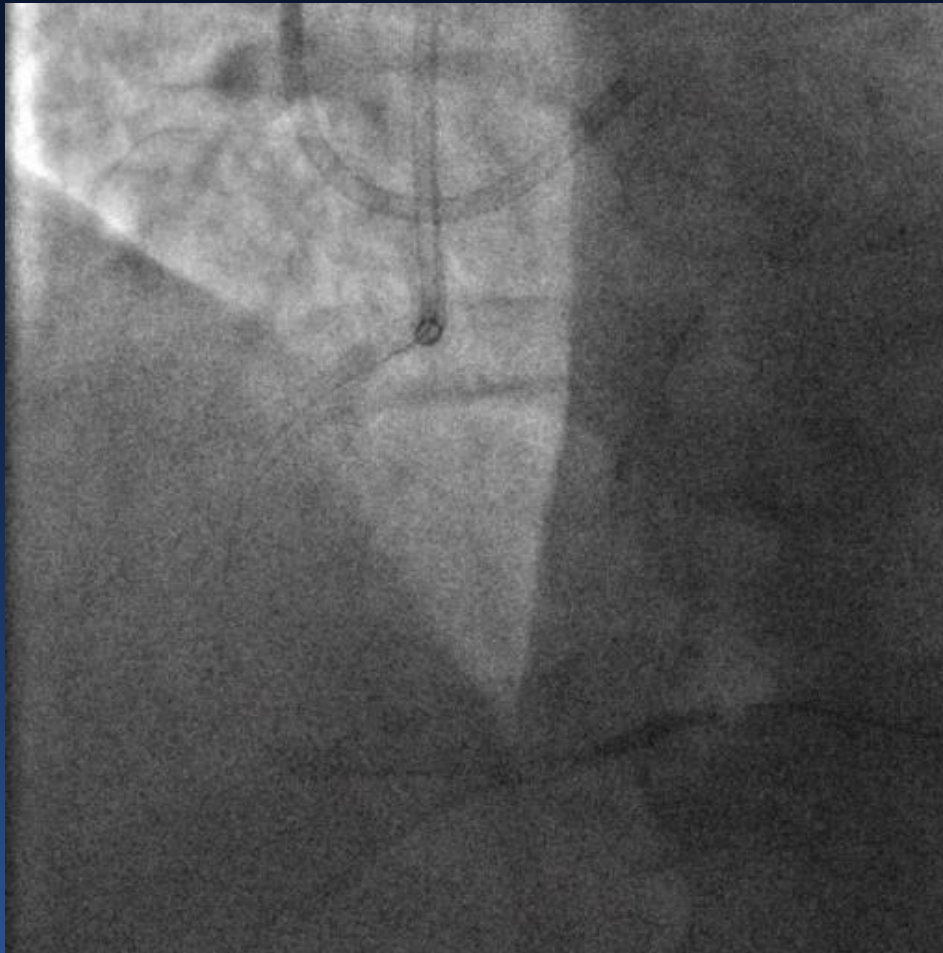
# Case 2-Baseline Angiogram



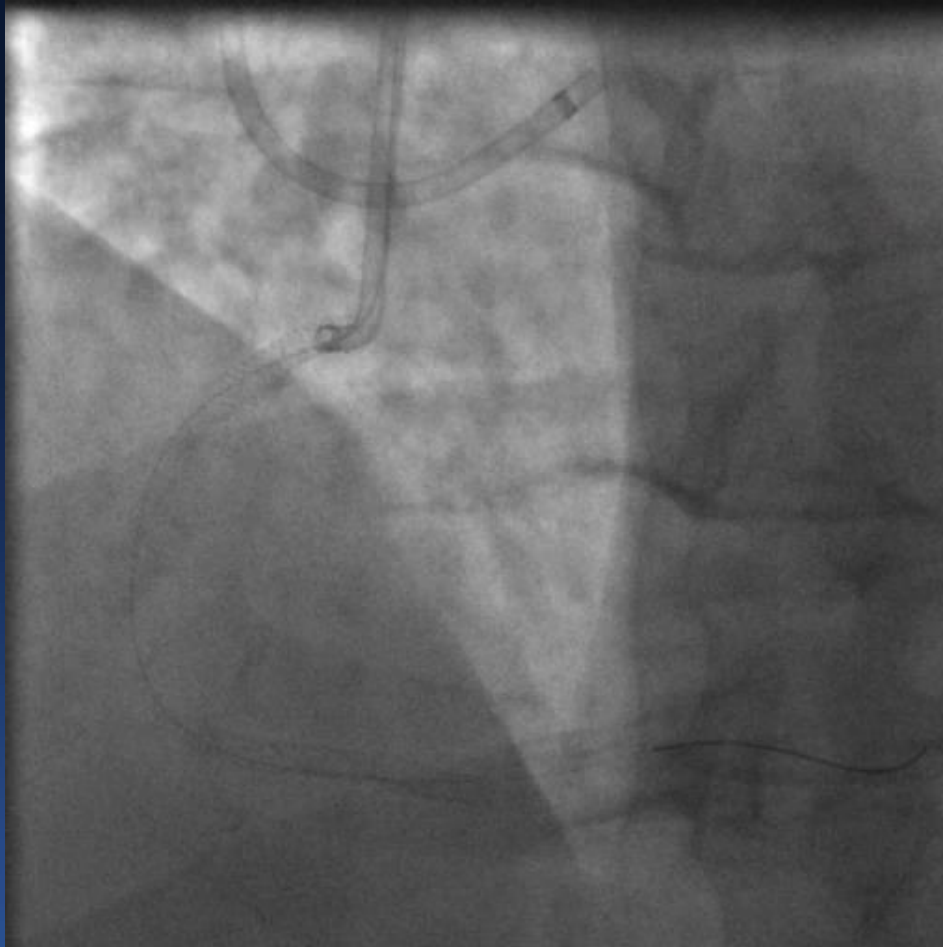
# CB-Reentry wttth StingRay Balloon



# CB-Release of Hematoma



# Final Angiogram







Thank you for your attention