

Sponsored by Boston Scientific Corporation

The Eluvia™ Drug-Eluting Vascular Stent System

New techniques and devices are extending the range of patients who can be treated by endovascular means.

BY ATHANASIOS DIAMANTOPOULOS, MD, PhD, EBIR

Peripheral artery disease (PAD) is estimated to affect approximately 12% to 14% of the general population today, and this percentage only increases with age (about 20% of adults older than 75 years are believed to be affected).¹ With an estimated 202 million individuals affected worldwide, PAD is considered a global pandemic. According to a recent meta-analysis conducted by Fowkes et al, the number of people living with PAD increased by 23.5% between 2000 and 2010.²

PAD often involves the superficial femoral artery (SFA) and/or proximal popliteal arteries. Percutaneous endovascular treatment of the femoropopliteal arteries has recently emerged as the first-line treatment option in many patients with PAD, and new techniques and devices have extended the range of patients who can be treated by endovascular means. Nevertheless, developing an ideal endovascular treatment for the SFA has been an elusive target.³ Unfortunately, restenosis and low patency rates remain the main limitations of such techniques due to the unique biomechanical properties of this arterial segment, as well as the formation of neointimal hyperplasia.

In this ongoing fight against restenosis, many technologies have been proposed including, but not limited to, plain balloons; bare-nitinol, self-expandable stents; drug-eluting stents (DESs); drug-coated balloons (DCBs); and covered stents.³ Comparing and analyzing the data from available studies of these technologies represents a huge challenge. A recent Bayesian network meta-analysis by Katsanos et al analyzed 16 randomized controlled trials and showed that immediate technical success is superior following the use of covered stents, whereas paclitaxel DESs and DCBs showed better long-term results in terms of reduced restenosis and target lesion revascularization.⁴ DCBs cannot replace stents when there is a need to treat immediate complications or

suboptimal postangioplasty results. Additionally, clinical data suggest DCBs are less effective than stents in treating calcified lesions.

In February, Boston Scientific Corporation received CE Mark approval for the Eluvia drug-eluting vascular stent system, a self-expanding nitinol DES designed for the treatment of lesions in the femoropopliteal arteries (Figure 1). Eluvia is the only DES for the SFA that utilizes the well-known antirestenotic drug paclitaxel in conjunction with a highly biocompatible polymer (the same polymer employed in the widely used Promus™ coronary stent [Boston Scientific Corporation]). This drug and polymer combination (named Sustend™) is uniquely formulated to




Figure 1. The Eluvia drug-eluting vascular stent system (Boston Scientific Corporation).

CASE STUDY: LONG, SEVERELY CALCIFIED SFA LESION

By Theodosios Bisdas, MD, PhD, and Giovanni Torsello, MD, PhD

A 67-year-old man with a history of coronary artery disease, hyperlipidemia, and carotid artery disease presented with claudication of the left leg. Angiography revealed a 25-cm severely calcified lesion extending the entire length of the SFA (Figure 2). The lesion also included an 80-mm total occlusion in the proximal segment of the SFA (Figures 3A and 4A).

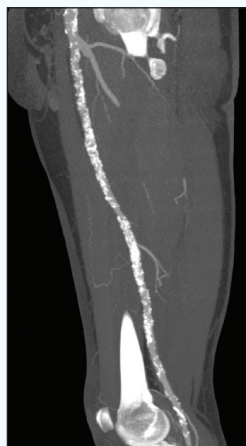

Figure 2.

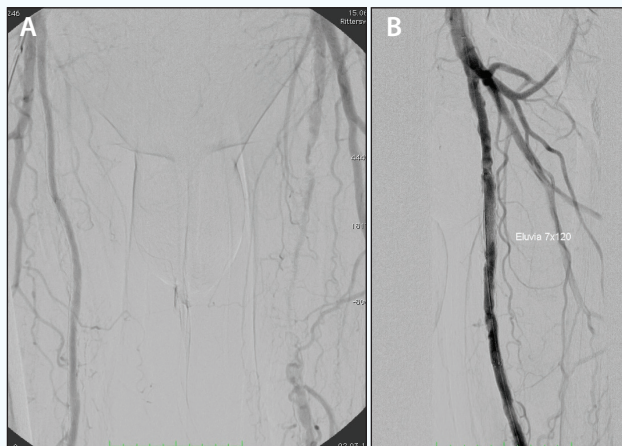


Figure 3.

Access to the lesion site was achieved through a transfemoral approach using a crossover technique through the right common femoral artery. After crossing the occlusion with a transluminal approach using a V-18™ guidewire (Boston Scientific Corporation) and a Quick-Cross™ support catheter (Spectranetics Corporation), angioplasty was performed with a 5- X 100-mm PTA balloon.

Following predilatation of the vessel, two Eluvia DESs were successfully deployed across the lesion: a 7- X 120-mm DES in the proximal SFA (Figure 3B) and a 7- X 150-mm DES in the distal SFA (Figure 4B). The lesion was then post-dilatated using a 6- X 120-mm PTA balloon.

The Eluvia stent demonstrated excellent performance even in a long, severely calcified lesion. The unique triaxial delivery system and the highly visible markers ensured precise placement of the stents, and the device demonstrated exceptional stability throughout the procedure.

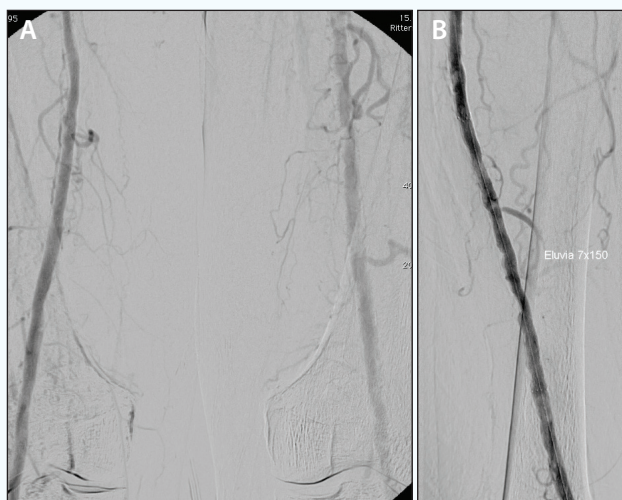


Figure 4.

Results from case studies are not necessarily predictive of results in other cases. Results in other cases may vary.

Theodosios Bisdas, MD, PhD

Assistant Professor for Vascular Surgery
Department of Vascular Surgery
St. Franziskus Hospital
University Clinic of Münster
Münster, Germany
Theodosios.Bisdas@SFH-MUENSTER.de
Disclosures: None.

Prof. Giovanni Torsello

Director
Center of Vascular and Endovascular Surgery
University Hospital Münster
Chief Physician
Department of Vascular Surgery
St. Franziskus-Hospital
Münster, Germany
giovanni.torsello@ukmuenster.de
Disclosures: None.

Sponsored by Boston Scientific Corporation

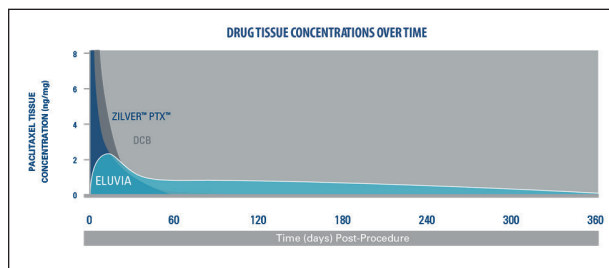


Figure 5. Eluvia versus Zilver® PTX (Cook Medical) paclitaxel release over time, based on preclinical pharmacokinetic analysis. Data for Eluvia on file at Boston Scientific Corporation. Data for Zilver PTX available from Dake MD, Van Alstine WG, Zhou Q, Ragheb AO. Polymer-free paclitaxel-coated Zilver PTX stents—evaluation of pharmacokinetics and comparative safety in porcine arteries. J Vasc Interv Radiol. 2011;22:603-610.

sustain drug release for more than 1 year to match the timing of restenosis in the femoropopliteal arteries. The Eluvia stent is built on the Innova™ stent platform (Figure 5), optimized for flexibility, strength, and fracture resistance, and is deployed on a 6-F low-profile triaxial delivery system for accurate stent placement.

Eluvia demonstrated promising results in the MAJESTIC trial.⁵ MAJESTIC is a prospective, multicenter, single-arm, clinical trial enrolling 57 patients across multiple sites in Europe, Australia, and New Zealand. The trial included relatively challenging lesion characteristics including severe calcification in 65% of the lesions and total occlusions in 46% of the lesions. More than 75% of the lesions involved the distal SFA and/or the proximal popliteal artery. The mean lesion length was 7.1 cm. In MAJESTIC, the Eluvia stent demonstrated a 12-month primary patency rate of 96.1%, accompanied by a target lesion revascularization rate of 3.8%, with no observed stent fractures and no amputations. These results represent the highest 12-month primary patency reported for an interventional treatment of femoropopliteal artery lesions among comparable trials. Also impressive was the 100% primary patency at 12 months in the diabetic patient subgroup. The 2-year results from MAJESTIC are expected to be presented at CIRSE in September 2016.

Currently, Boston Scientific Corporation is enrolling patients in the IMPERIAL trial, which is a randomized controlled trial enrolling 485 patients at up to 70 sites worldwide. This will be a single-blind noninferiority study that will randomize patients (2:1 randomization) to treatment with the Eluvia paclitaxel-eluting stent system versus the Zilver PTX paclitaxel-eluting stent system. The company has also announced two additional European trials: the EMINENT randomized controlled trial, which will include 750 patients and will compare the Eluvia stent versus bare-metal stents (2:1 randomization); and the REGAL registry, which will include 500 patients. The latter will be a real-world lesions registry. ■

1. Shammas NW. Epidemiology, classification, and modifiable risk factors of peripheral arterial disease. Vasc Health Risk Manag. 2007;3:229-234.
2. Fowkes FG, Rudan D, Rudan I, et al. Comparison of global estimates of prevalence and risk factors for peripheral arterial disease in 2000 and 2010: a systematic review and analysis. Lancet. 2013;382:1329-1340.
3. Diamantopoulos A, Katsanos K. Treating femoropopliteal disease: established and emerging technologies. Semin Intervent Radiol. 2014;31:345-352.
4. Katsanos K, Spiliopoulos S, Karunanithy N, et al. Bayesian network meta-analysis of nitinol stents, covered stents, drug-eluting stents, and drug-coated balloons in the femoropopliteal artery. J Vasc Surg. 2014;59:1123-1133.e8.
5. Müller-Hülsbeck S, Keirse KF, Zeller T, et al. Twelve-month results from the MAJESTIC trial of the Eluvia drug-eluting vascular stent system. Presented at: Cardiovascular and Interventional Radiological Society of Europe (CIRSE); September 27, 2015; Lisbon, Portugal.

CAUTION: The law restricts these devices to sale by or on the order of a physician. Indications, contraindications, warnings and instructions for use can be found in the product labeling supplied with each device. Information for the use only in countries with applicable health authority product registrations. Material not intended for use in France. © 2016 Boston Scientific Corporation. All rights reserved. Eluvia, V-18 ControlWire, and Promus™ are trademarks of Boston Scientific Corporation. All other trademarks are property of their respective owners. Caution: Investigational Device in the US. Limited by US law to investigational use only. Not available for sale in the US.

Athanasios Diamantopoulos, MD, PhD, EBIR

Consultant Interventional Radiologist
Department of Interventional Radiology
Guy's and St. Thomas' NHS Foundation Trust
Honorary Clinical Senior Lecturer
Division of Imaging Sciences
School of Medicine
King's College London, King's Health Partners
London, United Kingdom
athanasios.diamantopoulos@gstt.nhs.uk

Disclosures: Received honoraria for travel and lectures from Boston Scientific Corporation, Abbott Vascular, Cook Medical, and Cordis Corporation.